

Ophthalmology[®] ROUNDS

AS PRESENTED IN THE
ROUNDS OF THE DEPARTMENT
OF OPHTHALMOLOGY
AND VISION SCIENCES,
FACULTY OF MEDICINE,
UNIVERSITY OF TORONTO

Advances in Corneal Transplantation

BY DAVID S. ROOTMAN, MD, FRCSC

It has been 101 years since Dr. Eduard Zirm performed the first successful penetrating keratoplasty (PKP).¹ He operated on the eyes of an itinerant farm worker who had been blinded by alkali. In the ensuing 50 years, technical advances by such greats as Filitov, Castroviejo, and others have brought us into the era of successful corneal transplantation, where a 90% success rate is an accepted fact^{2,3} (Figure 1). Advances in the understanding of corneal immunology and rejection, microsurgical instrumentation, and sutures have made this a reality, and modern eye banking has been an integral part of the progress. However, the technique for standard penetrating corneal graft has remained largely unchanged over the past 40 to 50 years, and lamellar corneal transplants, while popularized in the last century by physicians such as Von Hippel, have not enjoyed great success due to difficulties with interface clarity.⁴ Therefore, while advances in retina, glaucoma, and other subspecialties rocketed forward, changes in corneal surgery have been slower. Recently, however, this trend has been reversed with the development of new techniques and devices for corneal transplantation. This issue of *Ophthalmology Rounds* presents an overview of the advances in corneal transplantation.

Endothelial transplantation

Once the importance of the corneal endothelium as the water pump for the cornea was recognized, the application of full-thickness keratoplasty for endothelial disease became the treatment of choice. Disorders such as Fuchs' corneal dystrophy, aphakic corneal edema and later, pseudo-phakic corneal edema, became the predominant causes of endothelial failure and poor vision due to irregular astigmatism and clouding. It was not long before leading physicians such as Jose and Joaquin Barraquer of Barcelona and Bogata realized that replacing the entire cornea – when only the posterior 20 microns was diseased – may not be the best option. They conceived the “partial” lamellar transplant, performed under a flap to replace the posterior stroma and endothelium. This was facilitated by using a microkeratome, a device similar to a skin dermatome that allows the smooth resection of the corneal surface in a flap formation and internal trephination of a central disc and its replacement.⁵

While the concept was revolutionary, it did not seem to take hold and the ideas sat dormant for many years while corneal surgeons around the world continued to do full-thickness grafts (ie, PKP) for endothelial replacement. Although a great procedure with decent success, especially with the introduction of topical steroids, it had some unsolved problems. For example, a clear graft would be useless to the patient if a large amount of astigmatism, both regular and irregular, remained (Figures 1 and 2). As well, rejection – which occurred in <10% of cases – often led to graft failure. Weakening of the cornea, which led to easy disruption by minor trauma, was a lifelong problem for some patients and suture-related infections could ruin a good result.

Then, in the mid- to late-90s, a Dutch ophthalmologist, Gerrit Melles, revived the idea of replacing only the layer of the cornea impaired by endothelial failure.⁶⁻⁹ The concept was different from that elaborated by Barraquer decades before. Instead, Melles proposed removing the inner deep stroma, along with the endothelium on Descemet's



FACULTY OF MEDICINE
University of Toronto



Department of
Ophthalmology and
Vision Sciences

Department of Ophthalmology
and Vision Sciences
Jeffrey Jay Hurwitz, MD, Editor
Professor and Chair
Martin Steinbach, PhD
Director of Research

The Hospital for Sick Children
Elise Heon, MD
Ophthalmologist-in-Chief

Mount Sinai Hospital
Jeffrey J. Hurwitz, MD
Ophthalmologist-in-Chief

Princess Margaret Hospital
(Eye Tumour Clinic)
E. Rand Simpson, MD
Director, Ocular Oncology Service

St. Michael's Hospital
Alan Berger, MD
Ophthalmologist-in-Chief

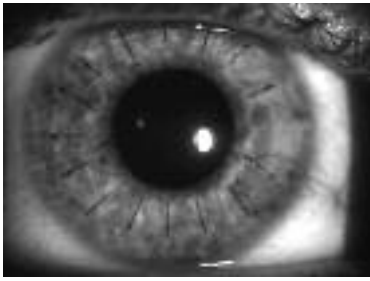
Sunnybrook Health
Sciences Centre
William S. Dixon, MD
Ophthalmologist-in-Chief

University Health Network
Toronto Western Hospital Division
Robert G. Devenyi, MD
Ophthalmologist-in-Chief

Department of Ophthalmology
and Vision Sciences,
Faculty of Medicine,
University of Toronto,
60 Murray St.
Suite 1-003
Toronto, ON M5G 1X5

The editorial content of
Ophthalmology Rounds is determined
solely by the Department of
Ophthalmology and Vision Sciences,
Faculty of Medicine, University of Toronto

Figure 1: Round penetrating keratoplasty, 10-0 interrupted and 11-0 running suture in place



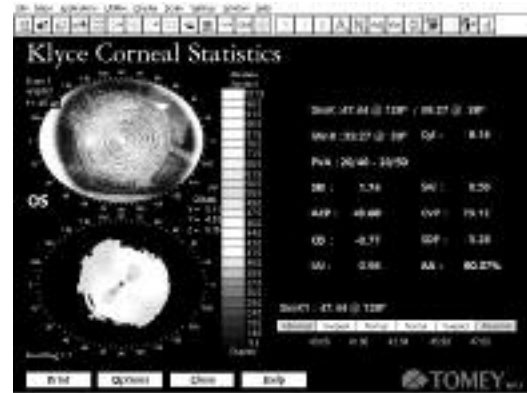
membrane, and replacing it with a thin lamellar disc from a corneal donor. He did this initial work as a research fellow with Dr. Perry Binder in San Diego, California, and persisted with this approach back in Holland. This led to the publication of the concept and the first successful endothelial transplant performed in humans towards the end of the 1990s. His technique was facilitated by the dissection techniques that he pioneered; doing what others had said was not doable. He used his keen sense of observation to notice that dissection over an air bubble produced a unique interface that reflected the edge of a dissecting knife and saw that this could be used to define and separate the deep layers of the cornea, allowing the surgeon to come within microns of the endothelium without penetrating Descemet's membrane.

Small rumblings of his ideas and techniques started to be heard in the corneal world in the early part of the new century. Some physicians, most notably Mark Terry from Portland, realized something exciting was happening and quickly went to learn about the new innovations of Dr. Melles. I, personally, was astounded by the success of the technique and immediately arranged to visit Dr Melles in Holland in 2001. Unfortunately, the hoof and mouth disease epidemic made travel to Holland and access to animal eyes difficult; therefore, my trip was postponed. In 2002, I traveled to Rotterdam and spent time with Dr. Melles, studying and learning his techniques. I later went to work with Mark Terry in Portland to observe the modifications of the techniques proposed by another great surgeon.¹⁰⁻¹⁵

Other centres have proposed a revival of the superficial flap with deep trephination that the Drs. Barraquer had designed,¹⁶ but problems with wound healing and irregular astigmatism convinced me that the internal techniques of Melles were the better alternative.

Melles called his technique, "posterior lamellar keratoplasty (PLK)," while Terry popularized the term, "deep lamellar endothelial keratoplasty (DLEK)" for his similar, though slightly different technique.

Figure 2: Topography after corneal transplant.g
Note "bow-tie" pattern of astigmatism

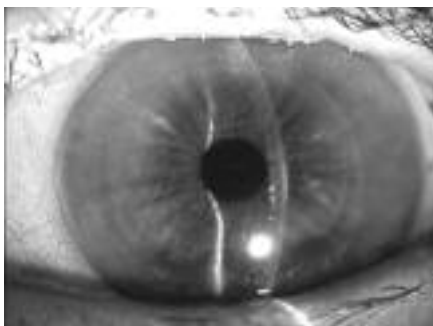

While Melles advocated dissection over a cushioning air bubble, Terry separated the lamella with fluid in the anterior chamber. The originally-devised technique includes the following steps:

1. Dissection of a corneal plane with specially-designed dissectors, splitting the cornea horizontally from limbus to limbus at about 85% (400 microns or so) from the surface via a limbal scleral tunnel.
2. Demarcation of a circle of 8 to 9 mm in the centre of the cornea. Originally, a specially-designed, intrastromal trephine was inserted into the corneal pocket and it performed the internal trephination into the anterior chamber. However, this maneuver was difficult and was later replaced by a free-hand internal cut with specially-designed scissors via the limbal incision.
3. Preparation of the donor lens in a similar fashion using a donor rim inserted into an artificial anterior chamber apparatus or done on a whole donor eye. The split cornea was then punched from the endothelial side to match the size of the internal cut on the recipient.
4. Insertion of the donor lens into the anterior chamber and positioning in the area of resection in the recipient. This was initially done by placing the donor lens on a spatula and inserting it into the anterior chamber with stroma-to-stroma apposition. This required a large 9 mm incision. Later, a "taco" like fold was done, with the endothelial surface touching the endothelial surface and inserting it through a 5 mm scleral tunnel incision. This changed the operation to a near-sutureless keratoplasty and, usually, one stitch alone was needed to close the wound.

The results of small series started to appear, primarily by Melles in Europe, and Terry in the United States. Dr. Terry formed the Endothelial Keratoplasty Group (EKG), comprised of surgeons around the world who were collaborating to share results and improve the pioneering techniques. The group meets

Figure 3: One week after a successful DLEK procedure keratoplasty. Note absence of sutures on surface



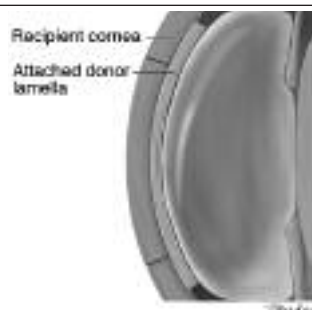
twice a year and has helped to move the field along at a rapid clip (Figure 3).

Meanwhile, Melles continued to innovate. The internal dissection proved to be a time-consuming and difficult technique to master and often produced an irregular interface. This may have limited visual outcomes to the 20/40 range and caused some physicians to be skeptical about the technique, limiting its widespread adoption. Melles proposed removing only Descemet's membrane, leaving a glassy smooth stromal surface exposed. The problem was then how to transplant Descemet's membrane only. This challenge has proved to be difficult since donor Descemet's membranes scroll up, making unfolding and placement in the eye difficult.

The suggestion then was to insert the new donor endothelium along with a thin stromal layer of approximately 100 microns. This is indeed what Melles did and called the new modification, "Descemet's stripping with endothelial keratoplasty (DSEK)" Figure 4. These advances were revealed by Melles in 2002 to 2004 and gradually have taken hold as an alternative to PLK or DLEK.²³ The thin donor piece is inserted into the eye and positioned in the anterior chamber with the aid of an air bubble. This helps remove interface fluid and allows the new donor endothelium time to begin pumping and forming the vacuum needed to hold the donor in place. Preliminary results were encouraging and seemed to be an alternative to the earlier techniques.¹⁷ Certainly, peeling off Descemet's membrane is far easier to do than performing the deep lamellar dissections needed in PLK and DLEK.

Another technical advance arrived to help improve the technique further. Microkeratomes had been around for some time, all based on Barraquer's original concept from the 1950s. They were improved through engineering and instrument development until the advanced, modified, Barraquer microkeratome was presented in the mid-1980s by Steinway Instruments (California, USA). It became

Figure 4: Diagrammatic representation of a DSEK or DSAEK procedure. Note the undisturbed recipient cornea with thin stromal layer apposed to the bare posterior stroma.

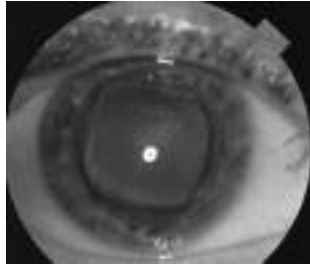


the first device to be commonly used and was adapted by Bausch and Lomb, Inc. (San Dimas, CA) for use in the laser-assisted in-situ keratomileusis (LASIK) procedure to correct for myopia, astigmatism, and hyperopia. Further adjustments were developed by this and other companies enabling more precise, smoother, and safer flaps.

LASIK is now the dominant procedure and millions of people worldwide have had their corneas "sliced open" using one of these devices. Moria Inc. (Antony, France), modified the keratome, applied turbo power to it, and coupled it with an artificial anterior chamber to hold the excised corneal donor. This enabled removal of a thick (400 microns) anterior cap with exquisite precision, leaving a posterior layer of about 150 microns with a very smooth stromal surface. This posterior layer, including stroma, endothelium, and Descemet's membrane, could be folded and inserted into a recipient with the Descemet's stripping procedure. Not only is the stromal surface smoother – eliminating concerns about interface scarring – but donor dissections can now be done without manual lamellar dissections. This combination is now termed "Descemet's stripping automatic endothelial keratoplasty (DSAEK)" and has exploded onto the cornea scene with a similar intensity as phacoemulsification for the cataract surgeon and LASIK for the refractive surgeon.

Interface problems, technical problems, and donor preparation problems are relatively minor compared with 5 years ago and the original PLK/DLEK procedures. However, donor problems still remain, with endothelial cell loss probably higher than with standard PK. There is also the expense associated with the modified microkeratome and no long-term comparative studies are available to verify the longevity of the technique compared with penetrating keratoplasty, the gold standard for endothelial disease. Unimagined complications, such as donor disc dislocation or nonadherence, may also occur in up to 30% of initial series.^{10,12}

Figure 5: Square transplant of Castroviejo

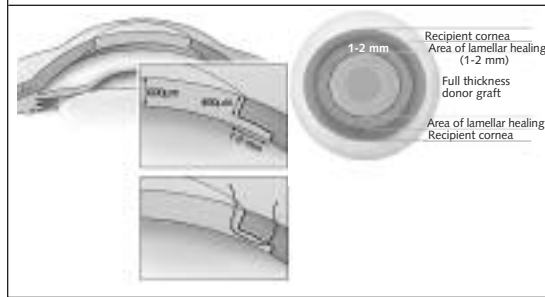


Modified penetrating keratoplasty

While endothelial failure is a major cause of corneal clouding necessitating repair, there are other disorders (eg, corneal scars, trauma, ectatic disorders, and dystrophies) that are not amenable to the posterior lamellar techniques described above. It is this author's opinion that we should not get rid of our trephines just yet and that there are still plenty of patients that can be helped by penetrating transplants. And yet, the need to solve the problems of penetrating surgery still exists for these patients. These are not new issues, the pioneers of transplantation looked for solutions to problems of wound apposition and healing. The modern, circular, straight-edge wound keratoplasty was, in fact, the end-result of years of thought, experimentation, and experience. We only need to examine the literature to appreciate the work of the masters and the problems they grappled with for keratoplasty surgery. Different wound configurations were proposed. For example, Castroviejo of Spain, and later New York City, designed the "square-shaped" keratoplasty and had success with this configuration (Figure 5).¹⁹ Francesetti and Barraquer examined various, two-step, rabbit-joint-like wound configurations;^{20,21} some had a wider anterior wound, while others had a wider posterior wound, but both had an intervening lamellar interface to improve wound surface area and healing. These ideas, however, remained dormant in the literature as the majority of the cornea world opted for circular keratoplasties assisted by the circular-shaped corneal trephine. Recently, however, Busin of Germany revived these partial lamellar techniques and adapted them to modern surgical instrumentation.¹⁷ He called his technique, "top hat" keratoplasty, since the outer, internal skirt makes the donor graft look like the "top hat" of yesteryear (Figure 6). This technique has the advantage of a greater stromal wound surface area, a larger transplanted endothelial area, and better wound

Figure 6: Top-hat penetrating keratoplasty.

Note the peripheral skirt that tucks into the periphery, giving a much greater stromal adhesion.



healing, allowing earlier suture removal without dehiscence. Ongoing studies may indicate the advantage of such techniques. Although there is a learning curve for mastering these methods, future studies will hopefully demonstrate that there is an associated considerable improvement.

Lamellar keratoplasty

For dystrophies and thinning disorders, penetrating grafts have dominated treatment for the past 5 decades. Though successful, the thought of removing healthy endothelium for anterior disease has always troubled the corneal surgeon. Why replace endothelium in a healthy 20-year-old with keratoconus and then subject him to the significant risk of endothelial rejection and permanent weakening of the eye with a penetrating wound?

For this reason, surgeons have looked for ways to obviate the need for a penetrating keratoplasty in such patients. Melles, the innovator in posterior lamellar surgery, has suggested alternative ways to remove the anterior 95% of the cornea, while safely retaining the host's Descemet's membrane and endothelium. Deep anterior lamellar keratoplasty (DALK) does just that.²³ Once again, using an air bubble as a guide and cushion, only the anterior stroma is removed and replaced. While technically challenging, this can be accomplished in many cases, thus saving a penetrating keratoplasty for those who truly have no other option. Other physicians, including Anwar of Egypt, have proposed separation of Descemet's membrane by injecting air into the stroma or fluid as an adjunct to dissection.²⁴ When successfully done, these deep lamellar surgeries avoid the interface problems of more superficial lamellar dissections, and generally produce results that are comparable to penetrating grafts. Endothelial rejection does not occur and although stromal rejection can occur,

it is usually mild and easily reversed with topical steroids.

Femtosecond laser-assisted keratoplasty (FLAK)

There has been another innovative engineering advance associated with refractive surgery. As mentioned above, the microkeratome revolutionized corneal refractive surgery, turning it into a generally safe and predictable procedure, although not one without complications. Most LASIK complications are attributable to the flap creation. In the mid-1980s, researchers began examining YAG laser technology as a way to do intrastromal ablation. The result was the Femtosecond laser, not as an intrastromal treatment device, but as a LASIK flap preparation device. IntraLase™ (Irvine, CA) was the first device to make it to the marketplace. By creating millions of small explosions in a raster (like a TV screen) pattern, all in the same plane, dissection of the cornea can be done without a keratome. This is accomplished transepithelially, without the need for the corneal friction associated with the standard microkeratome. The level of precision and thickness of the flaps are controlled to a much higher degree and limitations associated with the blade are overcome. Vertical flap edges and more planar flaps can be created. However, this is not the most exciting part for the cornea surgeon; instead it is the spin-off created by the device. Any type of corneal cut can be produced – vertical, horizontal, oblique, oval, circular, or custom. As well, the edge does not have to be straight; it can have a “top hat” configuration or a “zig-zag” shape (As presented by W. Culbertson at the Canadian Ophthalmological Society in Toronto, June 2006). This may improve wound apposition and healing and lessen astigmatism. Not only can we now make a cut that conforms to our imagination, but it can be done with software control. IntraLase has produced modifications for their “flap maker” and have turned it into a device that can be used in almost all corneal surgeries. While it is expensive technology, this author believes that it holds the key to performing successful corneal surgery in the future.

Conclusion

All the above techniques, anterior and posterior lamellar keratoplasties, arcuate incisions, and penetrating wound configurations can be better and more precisely performed with Femtosecond laser assistance. However, there are still bridges to cross. For instance, current tech-

nology depends on flattening the corneal surface (applanation) in order to cut. The engineering hurdles involved with creating a curved surface will eventually be overcome so that even distorted corneas can be precisely cut, likely with surface topographical guidance.

Ophthalmologists are fortunate to be living during this era of change in all fields of ophthalmology. Some of the innovations that we now take for granted were only dreams during the last generation. A combination of new technology and innovative “out-of-the box” thinking will likely provide even greater accomplishments in the future. One must respect the brilliance of our predecessors because their work fostered many of the ideas that are being developed today and there are now ways to implement these ideas. If we have learned anything, it is that most of what is new today was thought of by someone a long time ago. The task is up to us to find these treasures and apply them to modern times.

References:

1. Corneal Transplantation: A History in Profiles. In: Mannis MJ, Mannis AA. *Hirschberg History of Ophthalmology, The Monographs*, Vol 6. J.P. Wayenborgh:Belgium,1999:131.
2. Corneal Transplantation: A History in Profiles. In: Mannis MJ, Mannis AA. *Hirschberg History of Ophthalmology, The Monographs*, Vol 6. J.P. Wayenborgh:Belgium,1999:171-191.
3. Corneal Transplantation: A History in Profiles. In: Mannis MJ, Mannis AA. *Hirschberg History of Ophthalmology, The Monographs*, Vol 6. J.P. Wayenborgh:Belgium,1999:205-226.
4. Corneal Transplantation: A History in Profiles. In: Mannis MJ, Mannis AA. *Hirschberg History of Ophthalmology, The Monographs*, Vol 6. J.P. Wayenborgh:Belgium,1999:105-115.
5. Barraquer J, Rutllan J. *Microsurgery of the Cornea*. Ediciones Scriba, SA: Barcelona, Spain;1984:125,289,292.
6. Alio JL, Shah S, Barraquer C, Bilgihan K, Anwar M, Melles GR. New techniques in lamellar keratoplasty. *Curr Opin Ophthalmol* 2002;13(4):224-9.
7. Melles GR, Lander F, Nieuwendaal C. Sutureless, posterior lamellar keratoplasty: a case report of a modified technique. *Cornea* 2002;21(3):325-7.
8. Melles GR, Lander F, Beekhuis WH, Remeijer L, Binder PS. Posterior lamellar keratoplasty for a case of pseudophakic bullous keratopathy. *Am J Ophthalmol* 1999;127(3):340-1.
9. Melles GR, Eggink FA, Lander F, et al. A surgical technique for posterior lamellar keratoplasty. *Cornea* 1998;17(6):618-26.
10. Terry MA, Ousley PJ. Deep lamellar endothelial keratoplasty: early complications and their management. *Cornea* 2006 Jan;25(1):37-43.
11. Terry MA, Ousley PJ. Deep lamellar endothelial keratoplasty visual acuity, astigmatism, and endothelial survival in a large prospective series. *Ophthalmology* 2005;112(9):1541-8.
12. Ousley PJ, Terry MA. Stability of vision, topography, and endothelial cell density from 1 year to 2 years after deep lamellar endothelial keratoplasty surgery. *Ophthalmology* 2005; 112(1):50-7.
13. Terry MA, Ousley PJ. Small-incision deep lamellar endothelial keratoplasty (DLEK): six-month results in the first prospective clinical study. *Cornea* 2005;24(1):59-65.
14. Terry MA, Ousley PJ. Replacing the endothelium without corneal surface incisions or sutures: the first United States clinical series using the deep lamellar endothelial keratoplasty procedure. *Ophthalmology* 2003;110(4):755-64; discussion 764.
15. Terry MA, Ousley PJ. Deep lamellar endothelial keratoplasty in the first United States patients: early clinical results. *Cornea* 2001;20(3):239-43.
16. Busin M, Arffa RC, Sebastiani A. Endokeratoplasty as an alternative to penetrating keratoplasty for the surgical treatment of diseased endothelium: initial results. *Ophthalmology* 2000; 107(11):2077-82.

17. Busin M. A new lamellar wound configuration for penetrating keratoplasty surgery. *Arch Ophthalmol* 2003;121(2):260-5.
18. Price MO, Price FW Jr. Descemet's stripping with endothelial keratoplasty comparative outcomes with microkeratome-dissected and manually dissected donor tissue. *Ophthalmology* 2006;113(11):1936-42
19. Corneal Transplantation: A History in Profiles. In: Mannis MJ, Mannis AA. *Hischberg History of Ophthalmology, The Monographs*, Vol 6. J.P. Wayenborgh:Belgium,1999:209.
20. Corneal Transplantation: A History in Profiles. In: Mannis MJ, Mannis AA. *Hischberg History of Ophthalmology, The Monographs*, Vol 6. J.P. Wayenborgh:Belgium,1999:313. J.P.
21. Barraquer J, Rutllan J. *Microsurgery of the Cornea*. Ediciones Scriba, SA: Barcelona, Spain;1984:292.
22. Melles GR, Lander F, Rietveld FJ, Remeijer L, Beekhuis WH, Binder PS. A new surgical technique for deep stromal, anterior lamellar keratoplasty. *Br J Ophthalmol* 1999;83(3):327-33.
23. Melles GR, Wijdh RH, Nieuwendaal CP. A technique to excise the Descemet membrane from a recipient cornea (descemetorhexis). *Cornea* 2004;23(3):286-8.
24. Anwar M, Teichmann KD. Deep lamellar keratoplasty: surgical techniques for anterior lamellar keratoplasty with and without baring of Descemet's membrane. *Cornea* 2002;21(4):374-83.

Dr. Rootman is a physician at the University Health Network and the Hospital for Sick Children, and an Associate Professor at the University of Toronto, Toronto, Ontario.

Abstract of Interest

Descemet's Stripping with Endothelial Keratoplasty Comparative Outcomes with Microkeratome-Dissected and Manually Dissected Donor Tissue.

PRICE MO, PRICE FW JR., INDIANAPOLIS, INDIANA.

PURPOSE: To compare outcomes with 2 donor dissection methods for Descemet's stripping with endothelial keratoplasty (DSEK).

DESIGN: Retrospective, comparative, nonrandomized case series.

PARTICIPANTS: Three hundred thirty consecutive transplants, 114 with manually dissected and 216 with microkeratome-dissected donor tissue.

METHODS: Donor posteriorstroma/endothelium was transplanted, after stripping recipient Descemet's membrane/endothelium and dissecting the donor tissue by hand or with a microkeratome.

MAIN OUTCOME MEASURES: Incidences of donor perforation and donor detachment were compared for all eyes. Visual and refractive outcomes were compared for the first 100 consecutive eyes in each group.

RESULTS: Visual recovery was faster with microkeratome-dissected donor tissue, as evidenced by statistically better best spectacle-corrected visual acuity (VA) in that group 1 month after surgery ($P = 0.015$). Best spectacle-corrected VA was statistically comparable for the 2 groups preoperatively and 3 and 6 months postoperatively. Best spectacle-corrected VA was not correlated significantly with postoperative central corneal thickness ($P = 0.25$). Corneal thickness was significantly higher in the microkeratome group (690 ± 77 μm , compared with 610 ± 62 μm after hand dissection; $P < 0.0001$). Mean refractive astigmatism was 1.5 diopters (D) preoperatively and 6 months postoperatively in both groups. Spherical equivalent refraction did

not change in the microkeratome group ($P = 0.64$), but increased by 0.66 D in the hand dissection group ($P = 0.0007$). Methods designed to remove fluid from the donor/recipient graft interface ultimately reduced the detachment rate to $< 1\%$ (1 in the last 140 cases). No donor perforations occurred in 216 microkeratome dissections, compared with 5 in 114 hand dissections ($P = 0.002$).

CONCLUSIONS: Microkeratome dissection reduced the risk of donor tissue perforation, provided faster visual recovery after DSEK, and did not alter the refractive outcome.

Ophthalmology 2006;113(11):1936-42.

University of Toronto, Department of Ophthalmology

Upcoming events

- January 25, 2007** VPP Dr. Steve Charles, Memphis, Tennessee
25 Gage Vitrectomy for Retinal Detachment Repair
- March 1, 2007** VPP Dr. Jurij Bilyk, Philadelphia, Pennsylvania
Advances in Orbital Imaging
- March 8, 2007** VPP Dr. Joseph Mikhael, PMH, Toronto
Physician/Patient Communication —
More than Just Talking
- March 29, 2007** VPP Dr. Ken Romanchuk, Calgary, Alberta

Note: This year's (September 2006 to May 2007) VPP rounds will be held at Sunnybrook Health Sciences Centre, 2075 Bayview Avenue, Toronto, 'E' Wing, Ground Fl, Room EG61 at 5:30PM – 7:30PM.

The Toronto Cataract Course

Cataract Surgery: Rise of the Machines

Saturday, February 3, 2007

The Old Mill Inn, Toronto

To view Advance Notice/Program brochure:

www.cme.utoronto.ca/PDF/OPT0701.pdf

The 18th Annual Jack Crawford Day Pediatric Ophthalmology Conference: Strabismus for the Community

Friday, March 30, 2007

The Hospital for Sick Children, Toronto

To view Advance Notice/Program brochure:

www.cme.utoronto.ca/PDF/OPT0703.pdf

For information on the 2 courses above: Tel: 416.978.2719

Toll Free: 1.888.512.8173 Fax: 416.946.7028

E-mail: ce.med@utoronto.ca Website: www.cme.utoronto.ca

Disclosure Statement: Dr. Rootman has no disclosures to announce in association with the contents of this issue.

Change of address notices and requests for subscriptions for *Ophthalmology Rounds* are to be sent by mail to P.O. Box 310, Station H, Montreal, Quebec H3G 2K8 or by fax to (514) 932-5114 or by e-mail to info@snellmedical.com. Please reference *Ophthalmology Rounds* in your correspondence. Undeliverable copies are to be sent to the address above. Publications Post #40032303

This publication is made possible by an unrestricted educational grant from

Novartis Ophthalmics

© 2006 Department of Ophthalmology and Vision Sciences, Faculty of Medicine, University of Toronto, which is solely responsible for the contents. Publisher: SNELL Medical Communication Inc. in cooperation with the Department of Ophthalmology and Vision Sciences, Faculty of Medicine, University of Toronto. [®]*Ophthalmology Rounds* is a registered trademark of SNELL Medical Communication Inc. All rights reserved. The administration of any therapies discussed or referred to in *Ophthalmology Rounds* should always be consistent with the approved prescribing information in Canada. SNELL Medical Communication Inc. is committed to the development of superior Continuing Medical Education.